SCIENTIFIC ARCHIVES OF DENTAL SCIENCES (ISSN: 2642-1623)

Volume 4 Issue 6 June 2021

Case Report

Digital Workflow for Multidisciplinary Approach to the Functional and Esthetic Rehabilitation of the Smile: Fully Digital Versus Traditional Protocol

Ubiracy Gaião[1], Talyta Duarte[1], Ana Carolina Portes Pasmadjian[2], Gabriela Resende Allig[2] and Leonardo Fernandes da Cunha[3]*

[1]*Professor, Department of Dentistry, Positivo University, Curitiba, PR, Brazil*

[2]*Master Student, Department of Dentistry, School of Health Sciences, University of Brasília (UnB), Brasília, DF, Brazil*

[3]*Professor, Department of Dentistry, School of Health Sciences, University of Brasília (UnB), Brasília, DF, Brazil*

***Corresponding Author:** Leonardo Fernandes da Cunha, Professor, Department of Dentistry, School of Health Sciences, University of Brasília (UnB), Brasília, DF, Brazil.

Received: April 07, 2021; **Published:** May 15, 2021

Abstract

Integrated treatments (periodontal-occlusal-restorer) can be performed in a totally digital way and patient's request is dictated by these resources. This case report involves a young female who presented esthetic dissatisfaction and fracture in composite resin restorations. Clinical examination revealed inadequate canine guidance in lateral excursion, and the upper right canine presenting a gingival difference in relation to left. The treatment plan included the digital planning with intraoral, extraoral photographs and intraoral scans allows for aesthetic planning, as well as previews through the software, being especially helpful when the treatment involves periodontics. Digital waxing and evaluation with the virtual articulator in the current software collaborates fundamentally for the evaluation of the anterior and lateral disocclusion guides, favoring the longevity of the restorative treatment. Additionally, the mock-up and provisional prosthesis can be machined, presenting an evolution in relation to the adaptation and a decrease in time when compared to the traditional method. Once the provisional prosthesis has been approved, the milling machine is capable of machining exactly the same size and shape as previously demonstrated to the patient, thus avoiding problems of aesthetic or occlusal differences inherent in the traditional process. Esthetic results and patient satisfaction were monitored for 18 months and were very satisfactory. Clinical significance: at all stages, the digital protocol for integrated treatments is predictable and efficient, allowing easy diagnosis, improved communication with the patient, clinical and prosthetic work safety and treatment longevity.

Keywords: *Digital Smile Design; Esthetic Dentistry; Esthetic Parameters; Digital Planning*

Introduction

Integrated clinical treatments have always been a challenge for clinicians. Nowadays, it is possible for all stages of integrated rehabilitation treatments to be performed in digital form. However, to achieve success with the digital protocol, the details and adaptations in relation to the traditional method need to be established.

Digital smile planning has been presented as a tool to strengthen the diagnostic view and improve communication and predictability during treatment. With a simplified photographic protocol, the digital planning presents simple steps to evaluate the size, shape and position of the teeth, as well as the gingival and incisal contours [1]. Digital smile planning has been shown to be efficient, especially when the treatment involves an increase in length in the gingival region, a procedure that generates much fear, as well as many doubts and disappointments in patients [2].

Excellent restorative treatment involves the success of aesthetic, functional (occlusal), and biological (periodontal) aspects

[1,2]. Photographs associated with the initial scanning can guide functional issues in the program through a virtual articulator. The virtual articulator can help to diagnose, communicate and evaluate the increase in the incisal edges for the restoration of the anterior and lateral disocclusion guides [2,3].

The mock-up and provisional prosthesis are tools to provide the patient and dentist with more information during the diagnostic phase and clinical intervention [4,5]. Through the digital method, the mockup and provisional prosthesis can be machined, thus avoiding cervical excesses and occlusal adjustments resulting from material distortions. During the mock-up or provisional design, the software demonstrates the retentive areas and allows the professional to carry out selective abrasion with a diamond tip in these regions so that the mock-up can be positioned and evaluated in the mouth. The guide used for the mock-up can also be used for temporary restorations, thus decreasing time and cost.

Although scans have become increasingly popular in dentistry, the principles of traditional molding and scanning are the same. When molding an isolated element or single quadrant, the risk of errors is low, however, as the molding or scanning area increases, as in integrated rehabilitation cases, accuracy can be affected [6]. The finishing of the preparations must be well defined so that the boundary of the restoration edge is accurate. Placement of the retraction wire to expose the margin of the preparation, drying of hard and soft tissues, and the absence of blood are essential for acquisition of the images. Antagonist scanning and digital impression registration are indispensable.

Finally, the correlation mode offers the option to cut and paste the initial or digitalized provisional project, which is recommended for rehabilitations, as they maintain the planned functional and aesthetic parameters [7]. Subsequently, the artistic work can be performed with the prosthetic by means of textures and extrinsic characterization of the ceramics [8-11], especially in extremely thin ceramics, but maintaining the digital design.

Objective of the Study

The objective of this work is to report, through a clinical case, an integrated smile rehabilitation following a fully digital protocol.

Case Presentation

A young female patient came to the clinic to report dissatisfaction with the shape and size of her teeth, fractures in composite resin restorations of the upper anterior teeth, and the right canine presenting a gingival difference in relation to the left canine (Figure 1A). Initially, photos were taken of the smiling face with a digital camera and then the photos were inserted into the digital smile planning program (DSD App). In the next stage of the program, the teeth height and width ratio lines were determined by following the distal central incisors as the width reference and the smile line of the upper and lower lips as the base and top reference of the height/width ratio. In this case the gingival re-contouring will be carried out to accompany the upper lip line in the smile, thus, the format can be changed freely, without respecting the gingival contour as in cases where no gingival intervention is performed. The program offers different teeth formats (Figure 1B). This new contour can be filled in to make it easier for the operator to see at this moment.

The program shows the final simulation and the two smile pictures, with and without the digital simulation (before and after) (Figure 1C). Once the digital planning is approved by the patient and the professionals involved, the measurements can be taken from the difference between the preoperative location of the cervical areas of the teeth compared to the ideal location. In this case, gingival plasticity was recommended following the digital planning and 3 months were expected for healing.

Figure 1: Initial appearance of the patient's smile. She was dissatisfied with the shape, size, and color of the teeth. Detail of anterior teeth, showing imbalance of upper gingival arch harmony and resin restorations between central incisors. B: The tooth shape is selected. In this case the gingival re-contouring will be performed to accompany the upper lip line in the smile, thus, the format can be changed freely without respecting the gingival contour as in cases where no gingival intervention is carried out. C: The program shows the final simulation and the before and after two smile pictures, with and without the digital simulation. Final appearance of upper anterior teeth. Notice the harmony of color and shape provided by digital simulation.

Next, extra- and intraoral images were taken and the upper and lower arches were scanned for study of the restorative part of the case (Figure 2A). Size and shape planning (Figure 2B) were required to be evaluated for occlusion. For this evaluation, the model must be mounted in a virtual articulator. The lower incisors should be positioned at the level of the second aperture of the articulator as shown in figure 2C, at a distance of approximately 110 mm from the indicated portion. It is important to position the occlusal of the molars slightly beyond the purple plane indicated in the image of the virtual articulator. After this positioning of the lower arch, the upper model is articulated on it automatically, following the occlusal registration made during the scan. In this way it is possible to simulate the left and right lateral movements (Figure 2D), as well as the protrusion movement. When the digital planning was presented to the patient, some points were explained more clearly so as to be understood by the patient, especially the need to increase the length and volume of the teeth.

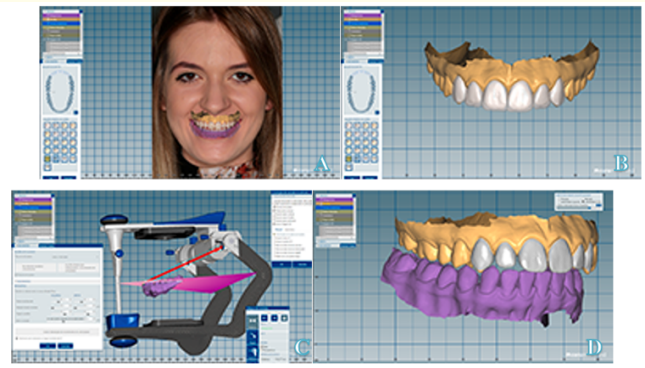

Figure 2: After 3 months of gingival re-contour healing, intraoral photography of the clinical case was performed (A) and intraoral scanning with Trios (3Shape). These data were entered into the software and the scanning overlap was performed with the initial image of the smiling face for virtual waxing (B). C: To carry out CAD planning, the model is mounted on the software articulator. The distance between the lower central incisors and the posterior/upper articulator should be approximately 110 mm with the occlusal of the molars slightly exceeding the plane delimited in purple in the software image. Then the upper model is articulated on the posterior. Top and bottom virtual model in articulator. D: Evaluation of right laterality.

At this point, the model was removed to enable visualization of the restorations, as can be seen in figure 3A, the regions in red represent retentive areas. Next, restorations were machined in resin to produce a mock-up (Figure 3B). Finally, after the virtual planning and machining of the project, the machined mock-up was tested in the patient to evaluate the proposal and gain permission for continuation of the treatment (Figure 3C). Due to the retentive areas, the resin was removed in the areas demonstrated in the software to enable mock-up testing (Figure 3D). After approval, the resin restorations were removed with rubbers and a sandpaper disc (Sof-Lex Pop-on; 3M). In the cervical region, the resin was removed with a No. 12 scalpel blade. A delimitation was made in the cervical region with diamond burs (Jota; Jota Brazil) and re-scanning was performed with retractor wire and gingival removal solution (3M) (Figure 4A). The color selection was made using the VITA 3D Master scale (0M3). The machined temporary restorations were delivered to the patient to use during the time in which the ceramics were being manufactured.

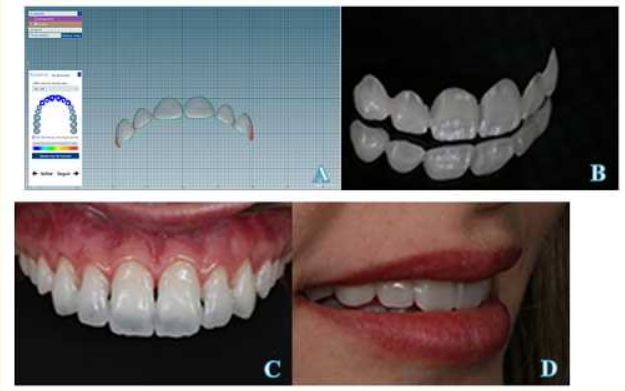

Figure 3: A: Evaluation in the design software of the restorations before milling the mock-up. Note in red the retentive areas that need to be ground to insert the milled mock-up (removal of resins from orthodontic brackets, canine tips, and distal areas that function as retentive areas). B: Mock-up milled resin (Vipi Blocks Color B1). C: Detail of the anterior teeth after removal of the retentive areas for insertion of the milled mock-up. D: Smile with the mock-up in the function of a temporary prosthetic after preparation of the teeth.

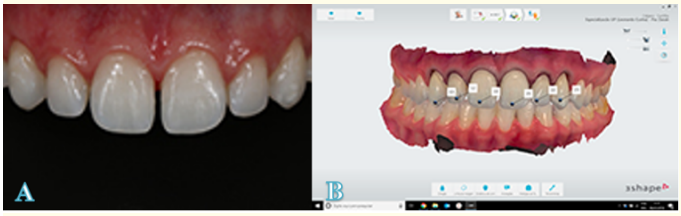

Figure 4: A- The resins were removed with a Sof-Lex (3M ESPE) disc of thick granulation (dark red) and No. 12 scalpel blades. A cervical demarcation was made with a spherical diamond tip. Final appearance of teeth after conservative cervical preparation. B- The retractor wire 000 (Ultrapack Ultradent) and gingival removal pulp (3M) were initially inserted, then, after waiting for 5 minutes, the preparations were scanned.

The laminates were made with machined ceramic with a lithium silicate reinforcement base (VITA Suprinity; VITA), following the same design as the patient-approved imaging and articulation software project. Afterwards, the restorations were individualized by the pigmentation technique (VITA AKZENT; VITA) (Figure 5). The inner faces of the ceramic restorations were conditioned with hydrofluoric acid for 20 seconds (GC). The surface was washed and then the silane (Silane; GC) agent was applied. The adhesive was applied but was not polymerized at this time. Modified insulation of the operative field and prophylaxis of the teeth was carried out. After protection of the adjacent teeth, the adhesive system (Gluma 2 Bond; Kulzer) was applied to the prepared teeth, according to the manufacturer's instructions. The cement was applied to the inside of the restoration and it was placed in position. The excess cement was removed from the proximal surface with dental floss and the buccal and lingual surfaces with an exploratory probe number 5. The material used for cementation was Nexus 3 Veneer White (Nexus 3; Kerr).

After cementation, the occlusal contacts were checked and adjusted, and proximal excesses were removed (Epitex; GC) sandpaper strips. The final appearance can be seen in figure 6A-6C.

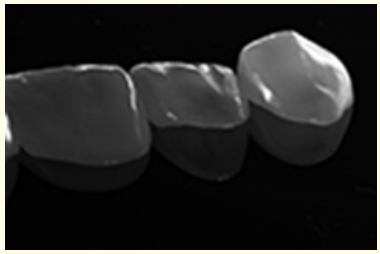

Figure 5: A- The ceramic was machined and extrinsic characterization was performed with pigments. A model was printed to support the ceramic during the refinement of the texture and points of contact by the prosthetist.

Figure 6: Detail of the smile and teeth of the patient's restorations after the digital protocol from the planning of periodontal surgery, articulation, provisional prosthetic, and ceramic restorations.

Discussion

Virtual planning programs are tools that can strengthen diagnostic views, improve communication, and improve treatment predictability, allowing for careful analysis of the patient's facial and dental characteristics, which may be neglected by clinical tests [1,4]. The DSD App program allows the planning steps to be systematized, helping the user not to forget or skip planning steps, and thus reducing the time for virtual project execution or failures. Despite being a recent program on the market, DSD App has shown promise due to its accessible and intuitive interface. It also allows

planning using photos and stl files from the intraoral scanning. One disadvantage of the program is the cost of the annuity, representing an extra expense when compared to programs like Keynote and PowerPoint. The facial analysis in the photograph not only provides information about the facial aesthetics, but also serves as a guideline to determine the shape of the teeth, of which there are several available in the software, that is, presenting concurrence of features between teeth and face, thus providing harmony to the patient's dento-facial composition [9]. Therefore, the periodontal surgery can be guided by the new contour delimited by the digital dento-facial planning.

When the treatment involves periodontal surgery, two plans should be made with the photographs, one for the surgery and another for the restorations, as the soft tissues will never heal exactly at the idealized location. It is now possible to export the digital planning to be printed accurately for the mock-up or surgical guide. For periodontal surgery this guide can be printed or machined directly from the demonstrated software. A limitation is not to allowing articulation of the planning, as performed in the following software demonstrated in this case, which is used by the laboratory. Therefore, the second virtual planning should be checked in specific laboratory software. In the case presented, a guide to periodontal surgery was not made since the gingival realignment was only to copy the right canine at the height of the left canine and refine the gingival zenith of the incisors. When the height and contour of the tooth set will be re-made, the guide is recommended and can be printed from the planning shown here [10]. Periodontal health and a healing time of 3 months should be respected for both traditional molding and scanning. This will allow non-inflammatory scanning (presence of exudate or blood) and correct positioning of soft tissues, thus allowing natural integration with future restorations [2].

The overlapping of dento-facial images in the stl. file generated by the scanning, as demonstrated in figure 2B and the Ceramill mind software allows a precise virtual articulation as demonstrated in figure 2D and 2E, thus minimizing occlusal adjustments in the mouth by the dentist and minimizing repetitions of length of the restorations by the prosthetist. From the images and articulation, it was found that it was possible to increase the length of the central incisors to favor aesthetics and protrusion, and to reduce the canine tips without causing prejudice to the disocclusion of canines, while maintaining an aesthetic length provided by previous periodontal surgery. In the software, the virtual waxing and evaluation of the amount of material that would be added were performed, as shown in figure 3A. The red areas demonstrate retentive areas that need to be ground to allow the insertion axis of the mock-up. Thus, the image acts as a grinding model to guide the professional in the retentive areas.

The mock-up and provisionary design are key steps in rehabilitation treatments. However, they are laborious for the professional, especially the cervical adaptation and occlusal adjustments, demanding time and cost. In the present clinical case, the mock-up was machined as shown in figure 3B. This makes the technique less sensitive to errors by the professional during insertion of the material, which can generate distortions and consequently repetition; thus resulting in higher cost. It is also more comfortable for the professional and patient as it is not necessary to remove gum excesses and eventual occlusal adjustments can be performed outside the mouth. The same set of mock-up restorations can be used as temporary prosthetics. The current blocks and milling machines allow the mock-up/provisionary prosthetic to have excellent texture, brightness, translucency, and finishing, thus favoring gingival health during the provisional phase; a phase that always concerned dentists if there was delay in the delivery of the ceramics from the laboratory or the patient postponed the consultation. If there is a fracture, as seen in the mesial cervical on the right side of figure 3B, small repairs can be easily made, or if the fracture is larger, another set can be machined quickly once the file is saved in the software. A disadvantage of this technique is the wear of the diamond tips for machining resins, so there is a tendency for laboratories to try to print these provisional designs, rather than machining them.

All intraoral scanners display excellent quality and reproduction fidelity. The scanner used in the present study is a reference in the world market and several studies report its efficiency. As in the traditional molding technique, the operator must be trained to capture the image appropriately, because each scanner has a different speed and movement to acquire the images [6,11]. In addition, well defined edges, healthy gingival tissues, well removed from the edges, and preparations without retentive areas, which are valid for the traditional technique, are also fundamental for the digital

technique. However, if any area is inadequate, this can be verified immediately and only that area scanned again, not the entire arch, dispensing with another clinical session. The digital technique does not dispense with soft tissue removal, with the exception of the supragingival margins. Therefore, in the case presented, in addition to the retractor wire, a gingival spacing paste was used instead of a second wire to allow better acquisition of the image by the scanner as shown in figure 4B. Some models of scanners are able to describe the color of the tooth, however, as in the traditional technique, the color evaluation must be performed before the preparations, as due to the dehydration of the teeth during the procedure and preparation and scanning, there may be a significant change in the interpretation, as demonstrated by the color difference in figure 4A and 4B.

Once the provisional design has been approved, it is sufficient to machine the same project to guarantee the same anatomy, size, and shape. If any alteration is made in the mouth, simply scan the mouth with the temporary design and work in the "correlation" mode [7]. This method avoids aesthetic alterations due to the application of the ceramic by the manual method, which can cause discomfort to the patient arising from differences in what was presented in the mock-up/provisional design or occlusal adjustments due to distortions of the injection process. Despite the digital scanning, a model was printed, as seen in figure 5A, to give support for the ceramic and visualization of the set during the prosthetic work to customize texture and extrinsic characterizations. The texture can also be fashioned during machining but greatly increases the milling time. In addition, manual texturing allows a differentiated naturalness to the work, as demonstrated in detail in figure 5B or in the mouth result of figure 6.

All available digital steps are both aesthetically and functionally useful tools to pre-verify patient expectations and increase treatment predictability, reducing working time and facilitating dental and prosthetic work. However, for the digital protocol, the principles of cavity preparation, biological properties of the medium and healing, and occlusal-functional properties are the same as those traditionally used throughout the last decades in dentistry.

Conclusion

Digital planning with intraoral and extraoral photographs and intraoral scans allows for aesthetic planning. Digital waxing and evaluation with the virtual articulator in the current software collaborates for the evaluation of the anterior and lateral disocclusion guides. The mock-up and provisional prosthesis can be machined, presenting a great evolution in relation to the adaptation and a decrease in time when compared to the traditional method. Once the provisional prosthesis has been approved, the milling machine is capable of machining exactly the same size and shape as previously demonstrated to the patient. Thus, the digital protocol for integrated treatments is predictable allowing easy diagnosis and efficient.

Bibliography

1. Coachman C, Calamita M. Digital smile design: a tool for treatment planning and communication in esthetic dentistry. Quintessence of Dent Technol. 2012;35:103-112.
2. Da Cunha LF, Pedroche LO, Gonzaga CC, Furuse AY. Esthetic, occlusal, and periodontal rehabilitation of anterior teeth with minimum thickness porcelain laminate veneers. J Prosthet Dent. 2014;112:1315-1318.
3. Zanardi PR, Laia Rocha Zanardi R, Chaib Stegun R, Sesma N, Costa BN, Cruz Laganá D. The Use of the Digital Smile Design Concept as an Auxiliary Tool in Aesthetic Rehabilitation: A Case Report. Open Dent J. 2016;10:28-34.
4. Reshad M, Cascione D, Magne P. Diagnostic mock-ups as an objective tool for predictable outcomes with porcelain laminate veneers in esthetically demanding patients: a clinical report. J Prosthet Dent. 2008;99:333-339.
5. Gurel G, Morimoto S, Calamita MA, Coachman C, Sesma N. Clinical performance of porcelain laminate veneers: outcomes of the aesthetic pre-evaluative temporary (APT) technique. Int J Periodontics Restorative Dent. 2012;32:625-635.
6. Ender A, Mehl A. *In-vitro* evaluation of the accuracy of conventional and digital methods of obtaining full-arch dental impressions. Quintessence Int. 2015;46:9-17.

7. Da Cunha LF, Mukai E, Hamerschmitt RM, Correr GM. Fabrication of lithium silicate ceramic veneers with a CAD/CAM approach: a clinical report of cleidocranial dysplasia. J Prosthet Dent. 2015;113:355-359.

8. Da Cunha LF, Gugelmin BP, Gaião U, Gonzaga CC, Correr GM. Tooth movement with elastic separators before ceramic veneer treatment: Rearranging asymmetric diastemas by managing the horizontal distance. Quintessence Int. 2018;49:133-137.

9. Rufenacht CR. Fundamental of Esthetics. Quintessence Publishing Co. Inc., Chicago, Il, 1990.

10. Da Cunha LF, Kintopp CA, Baechtold MS, Correr GM, Gonzaga CC. Premium protocol for planning a periodontal-restorative approach: Conservative, predictable, and reproducible. Quintessence Int. 2017;48:549-454.

11. Lim JH, Park JM, Kim M, Heo SJ, Myung JY. Comparison of digital intraoral scanner reproducibility and image trueness considering repetitive experience. J Prosthet Dent. 2018;119:225-232.

Volume 4 Issue 6 June 2021